

Combination Therapies by Traditional Veterinary Medicine and Conventional Treatment for Demodicosis in a Dog

Pan-Chen Liu¹, Cheng-Hung Lai¹, Sang-Hun Kim², Kun-Ho Song² and Duck-Hwan Kim^{2*}

¹College of Veterinary Medicine, National Chung Hsing University, Taichung 40227, Taiwan, ²Research Institute of Veterinary Medicine and College of Veterinary Medicine, Chungnam National University, Daejeon 305-764, Korea

초 록: 수컷 미니어처 핀셔 (9 개월령, 체중: 2.3 kg)가 대만 중흥대학 부속동물병원에 피부병변을 주호소로 내원하였고, 전신 모낭충증으로 진단되었다. Laser-AP apparatus를 이용하여 7회에 걸쳐 laser 침치료를 실시하였다. 사용혈위는 GV-14 (대추), BL-13 (폐수), LI-11 (곡지), BL-40 (위중), ST-36 (족삼리), SP-6 (삼음교) 및 SP-10 (혈해) 이었다. 또한, ivermectin 수침 (0.1 ml, 1회, GV-1 (교소혈)에 10주간 실시하였다. 그리고, 십미폐독탕 (0.1 g/kg), 황련상청환 (0.1 g/kg) 및 오미소독음 (0.1 g/kg)을 각각 투여하였다 (BID, PO, 10주). 통상적인 치료로는 amoxicillin (20 mg./kg, BID, PO), cyproheptadine hydrochloride (4 mg/head, SID, PO) 및 pyridoxine hydrochloride (50 mg/head, BID, PO) 을 각각 투여하였다. 그 결과, 전신의 피부 병변은 거의 정상 수준으로 회복되었다. 따라서 본 환축은 전통수의학적 및 통상적인 치료의 병용요법으로 양호한 결과를 나타낸 개 모낭충증의 증례이다.

주요어: 전통수의학적 치료, 통상적인 치료, 개 모낭충증

Introduction

Canine demodicosis is a commonly encountered skin disease in small animal clinical practice and long term treatment is needed for complete recovery¹⁻⁵. In human medicine, laser acupuncture (AP) therapy has been used for the treatment of various human diseases, including acne vulgaris⁶⁻⁸, neurogenic pruritus⁹, pleurisy¹⁰, orthopedic disease¹¹ and bronchial asthma¹², and even anesthesia¹³.

However, as for AP treatment especially for treatment of canine skin disease, therapeutic effects by needle-AP, with cyanocobalamin¹⁴ and aqua-AP with antibiotics¹⁵ were investigated. There have been no reports on the therapeutic effect of laser-AP for the treatment of canine skin disease up to present, except some cases of induced disease¹⁶⁻¹⁹. Here, we report a case of canine generalized demodicosis had a favorable therapeutic response to laser AP, aqua-AP with ivermectin and administration of herbal medicine

*Corresponding author: 042-821-6756, dhkim@cnu.ac.kr

in combination with conventional treatment.

Case

Case history

A male Miniature Pinscher dog (9-month-old, BW: 2.3 kg) with the chief complaint of the skin disease was referred to the Veterinary Medical Teaching Hospital (VMTH), National Chung Hsing University (NCHU) in Taiwan. The patient had skin lesions over 8 months prior to admission. He was previously treated at a local veterinary clinic, but there were no clinical improvement. This case was diagnosed as generalized demodicosis by a scraping test at the initial admission.

Therapeutic findings

Laser AP was performed by using a laser AP apparatus [Traveller(TW 10/50), Biophoton Co., Saint Alban, France, frequency: 25, one minute/acupoint] from session 1 to session 7 (Fig 1). The used acupoints were GV-14 (Da Zhui), BL-13 (Fei Shu, both), LI-11 (Qu Chi, both), BL-40 (Wei Zhong, both), ST-36 (Zu San Li, both), SP-6 (San Yin Jiao, both) and SP-10 (Xue Hai, both), respectively (Fig.2). In addition, aqua-AP with ivermectin (Baymec[®], 10 mg/ml, Korea LTD, Seoul, Korea, 0.1 ml, Ivomec, once /week) was also done at GV-1 (Jiao Chiao) from sessions 1 to 10. Herbal medicines (KODA Co. Tao Yuan, Taiwan) including Shyr Wey Bai Du Tang (0.1 g/kg), Huang Lian Jie Du Tang (0.1 g/kg) and Wu Wey Shiao Dwu Yiin (0.1 g/kg) were administered BID, PO from sessions 1 to 10. As a conventional treatment, amoxicillin (amoxicillin granule[®], 20 mg/kg, China Chemical & Pharmaceutical Co., LTD, Taichung, Taiwan, BID, PO), cyproheptadine hydrochloride (Perian Tablet[®], 4 mg/head, De Jiao Pharmaceutical Co, Tao Yuan,

Taiwan, MID, PO) and pyridoxine hydrochloride (vitamin B6[®], 50 mg/head, Taiwan Chemical Co., Tao Yuan, Taiwan, BID, PO) were prescribed for this patient.

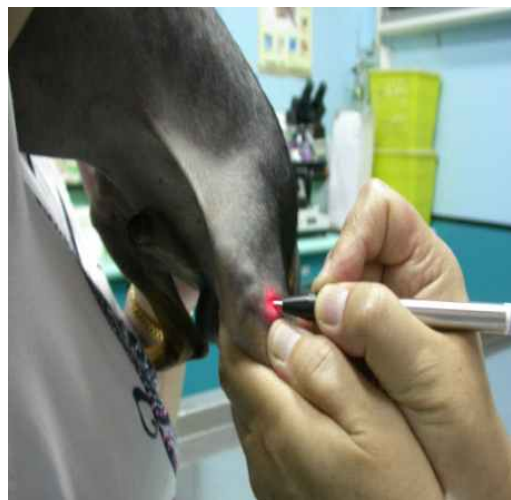

Fig 1. Laser-acupuncture at ST-36 (Zu San Li) acupoint.

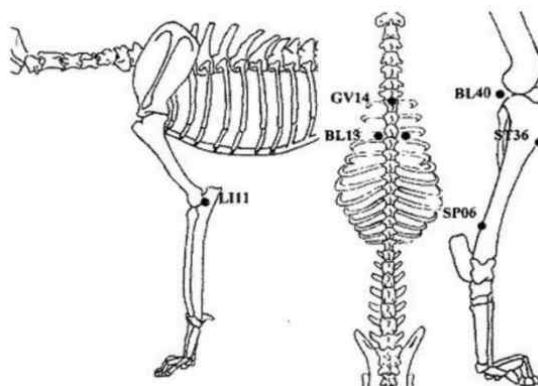


Fig 2. The used acupoints in this case.

The generalized skin lesions of the patient revealed almost normal through sessions 1 (Fig 1) to session 10 (Fig 2).

Discussion

In human medicine, Lihong⁷ reported a cure rate of 77.8% in the treatment group and 46.9% in the control group, indicating that He-Ne laser auricular irradiation plus body AP may produce better results for acne vulgaris. In addition, Gold⁶ described that lasers and light sources might be useful in the treatment of moderate to severe inflammatory acne vulgaris. Furthermore, Stellan⁹ mentioned the successful laser AP treatment of a girl with neurogenic pruritus of the abdomen and suggested that the laser was particularly useful when treating children.

In this study, the authors treated a case of canine demodicosis using laser AP, aqua-AP with ivermectin and administration of herbal medicine combined with conventional treatment. As a result, this patient had a favorable therapeutic response. Kim et al.¹⁶⁻¹⁹ reported that the laser-AP group had a relatively fast recovery from induced liver disease, spleen, pancreas and urinary bladder disease, thoracic disease and renal disease, compared

with electro-AP and needle-AP groups. In the present case, laser-AP may play a role in the treatment of skin lesions, like human acne vulgaris^{6,7,20}. The mechanism of laser AP should be elucidated in the near future. In addition, Jun et al.¹⁵ reported that aqua-AP with antibiotics was an effective treatment for 3 cases of canine demodicosis. However, the authors applied aqua-AP with ivermectin into the GV-lacupoint to improve the parasiticidal effect. The therapeutic effects of this method should be further elucidated by increasing the number of patients in future.

In addition, the authors administered herbal medicines in the current case. Shyr Wey Bay Du Tang contains Radix Bupleuri, Cortex Pruni, Radix Platycodi, Rhizoma Ligustici, Hoelen, Radix Angelicae Tuhuo, Radix Sapo Shinkoviae, Radix Glycyrrhizae, Rhizoma Zingiberis Recens and Herba Schizonepetae. The main effect of Shyr Wei Bay Du Tang is the removal of inner and outer Xi and detoxification, and it can be used for the treatment of conditions such as frunkle, pustule, phlegmone, lymphangitis, inflammation of

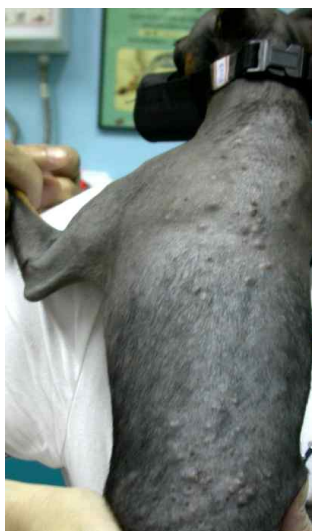

Fig 3. Skin lesions before treatment showed severe lesions can be seen over the body.

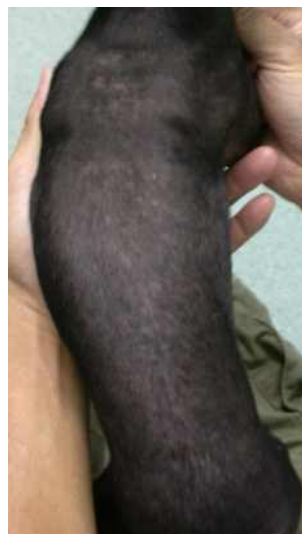

Fig 4. Recovered skin lesions after treatment reveal almost normal finding.

the mammary gland, sinusitis, dermatitis, eczema, rhinitis and otitis externa. Huang Lian Jie Du Tang contains *Rhizoma Coptidis*, *Radix Scutellariae*, *Cortex Phellodendri* and *Fructus Gardeniae*. The main benefits of Huang Lian Jie Du Tang are almost the same as Wu Wey Shiao Du Yiin and it is used for the treatment of various diseases including eczema, urticaria, dermatitis and skin pruritus etc. Wu Wey Shiao Du Yiin is composed of *Flos Lonicerae*, *Flos Chrysanthemi*, *Herba Turaxaci*, *Herba violae* and *Radix semiquiegiae*. The main benefits of Wu Wey Shiao Dwu Yiin are the removal of fever and detoxification. It is applicable for the treatment of frunkle, pustule and swelling in various kinds of skin, muscle, joint and organ, suppurative dermatitis and eczema etc²¹.

In the present report a favorable therapeutic response was thought to be attributed to the synergistic effects of laser-AP, aqua-AP with ivermectin and administration of herbal medicine combined with conventional treatment. More precise research on laser-AP with a greater number of patients with various skin diseases should be performed in future.

References

1. Duclos DD, Jeffers JG, Shanley KJ. Prognosis for treatment of adult-onset demodicosis in dogs: 34 cases. *J Am Vet Med Assoc* 1994; 204: 616-619.
2. Folz SD, Kratzer DD, Conklin RD et al. Evaluation of a topical treatment alone, and in combination with a detergent, for generalized demodicosis. *Vet Parasitol* 1985; 17: 165-172.
3. Holm BR. Efficacy of milbemycin oxime in treatment of canine generalized demodicosis: a retrospective study of 99 dogs (1995-2000). *Vet Dermatol* 2003; 14: 189-195.
4. Ristic Z, Medleau L, Paradis M et al. Ivermectin for treatment of generalized demodicosis in dogs. *J Am Vet Med Assoc* 1995; 207: 1308-1310.
5. Scott DW, Miller WH, Griffin CE. *Small animal dermatology*. 6th ed. St Louis: Saunders, 2001; 263-268.
6. Gold MH. Acne vulgaris: laser, light sources and photodynamic therapy-an update. *Expert Rev Anti Infect Ther* 2007; 5: 1059-1069.
7. Lihong S. He-Ne laser auricular irradiation plus body acupuncture for treatment of acne vulgaris in 36 cases. *J Tradit Chin Med* 2006; 26: 193-194.
8. Ortiz A, Van Vliet M, Lask GP et al. A review of lasers and light sources in the treatment of acne vulgaris. *J Cosmet Laser Ther* 2005; 7: 69-75.
9. Stellan A. The use of laser acupuncture for the treatment of neurogenic pruritus in a child-a case history. *Acupunct Med* 2005; 23: 31-33.
10. Milojevic M, Kuruc V. Laser biostimulation in the treatment of pleurisy. *Med Pregl* 2003; 56: 516-520.
11. Schuller BK, Neugebauer EA. Evidence for laser acupuncture in cases of orthopedic diseases: a systematic review. *Schmerz* 2008; 22: 9-15.
12. Milojevic M, Kuruc V. Low power laser biostimulation in the treatment of bronchial asthma. *Pregl* 2003; 56: 413-418.
13. Qin JN. Laser acupuncture anesthesia and therapy in People's Republic of China. *Ann Acad Med Singapore* 1987; 16: 261-263.
14. Schoen AM. *Veterinary Acupuncture*. St Louis: Mosby, 1994; 269-275.
15. Jun HK, Han JW, Oh HU et al. Injection-acupuncture combined by conventional treatment in canine demodicosis: case report. *J Vet Clin* 2007; 24: 432-436.

16. Kim MC, Shin ST, Byn HS et al. The studies on treatment of liver disease using lasers and acupuncture in dogs. *J Vet Clin* 1998; 15: 319-324.
17. Kim MC, Byun HS, Kim DH et al. The studies on treatment of spleens, pancreas and urinary bladder disease using lasers and acupuncture in dogs. *J Vet Clin* 1998; 15: 331-338.
18. Kim MC, Kim JM, Park JO et al. The studies on treatment of thoracic disease using lasers and acupuncture in dogs. *Vet Clin* 1998; 15: 339-345.
19. Kim MC, Byun HS, Jung JM et al. The studies on treatment of renal disease using lasers and acupuncture in dogs. *J Vet Clin* 1998; 15: 325-330.
20. Borelli C, Merk K, Plewig G et al. Light, laser and PDT therapy for acne. *Hautarzt* 2005; 56: 1027-1032.
21. Koda Pharmacological Co. *Chang Yong Fang Ji Shan Ji*, 7th ed. Taiwan: Tou Yuan, 2003: 9